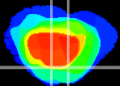
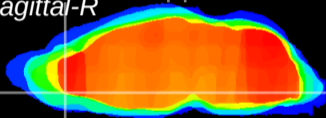


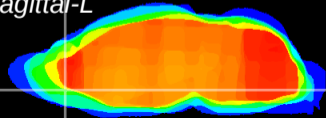
Coronal



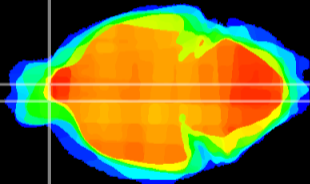
Sagittal-R



Sagittal-L



ViBrism: CX04108
Horizontal



OB posterior