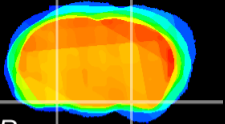
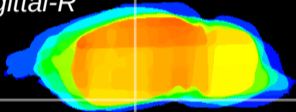


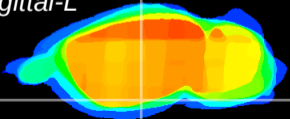
Coronal



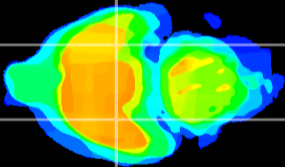
Sagittal-R



Sagittal-L



ViBrism: CX21662  
Horizontal



A posterior